

Antiulcer, analgesic and hepatoprotective activities of hydroalcoholic root extract of *Jurinea Dolomiaea Boiss* against carbon tetrachloride induced hepatopathy in rats

Mushtaq Ahmad Bhat^{*1}, Fairooz Ahmad Khan², Quazi Saifuddin², Dr.H.C.Kataria¹

¹Department of Chemistry, Govt. Geetanjali Girl's (Autonomous) P.G. College, Berasiya road Bhopal – 462038, Madhya Pradesh, India

²Department of Chemistry, Maulana Azad College of Arts Science and Commerce, Aurangabad –431001, Maharashtra, India
mushtaqbhat24434@gmail.com¹, fairoozch13@gmail.com², kaazisaif@gmail.com³, h-c kataria@yahoo.com⁴

Received: 19 Aug 2022,

Received in revised form: 08 Sep 2022,

Accepted: 13 Sep 2022,

Available online: 20 Sep 2022

©2022 The Author(s). Published by AI
Publication. This is an open access article
under the CC BY license

(<https://creativecommons.org/licenses/by/4.0/>).

Keywords— Antiulcer activity, Analgesic activity, hepatoprotective activity, *Jurinea dolomiaea* roots, CCl₄, SGOT, SGPT, ALP, total bilirubin, histopathology.

Abstract— The plant *Jurinea Dolomiaea Boiss* belonging to family *Astraceae* traditionally used in Ayurvedic system as antidiabetic, antioxidant, antibacterial, antitumor and also used in liver disorders. In this study, water and hydroalcoholic root extracts of *Jurinea dolomiaea boiss* was studied for antiulcer, analgesic and hepatoprotective properties against carbon tetrachloride induced hepatotoxicity in albino wistar rats. Hydroalcoholic extract of *Jurinea dolomiaea* root (100mg/kg and 200mg/kg p.o) were administered to the experimental rats for seven days. The hepatoprotective activity of hydroalcoholic extract of *Jurinea dolomiaea* roots were evaluated by estimation of SGOT, SGPT, ALP and total bilirubin. Histopathology of the liver was also studied. In the hydroalcoholic extract of *Jurinea dolomiaea* roots treated animals, the toxic effect of carbon tetrachloride was controlled significantly by restoration of the increased levels of SGOT, SGPT, ALP and total bilirubin as compare to the toxicant control. The hydroalcoholic extract of roots of *Jurinea dolomiaea* showed significant hepatoprotective activity.

I. INTRODUCTION

Lipid peroxidation is an important detorate reaction in food during storage and processing. It not only causes a loss in food quality but also be associated with some diseases such as carcinogenesis, mutagenesis, ageing, and arteriosclerosis [1]. The role of active oxygen and free radicals in tissue damage in such diseases, are becoming increasingly recognized [2]. Cancer, emphysema, cirrhosis, arteriosclerosis, and arthritis have all been correlated with oxidative damage. Recently, various Phytochemicals and their effects on health, especially the suppression of active oxygen species by natural antioxidants from teas, spices and herbs, have been intensively studied [3]. However, they are suspected of being responsible for liver damage and carcinogenesis in laboratory animals [4, 5]. *Jurinea dolomiaea* roots are used to treat stomachache in Indian

folk medicine [6]. In addition, the root is used to treat rheumatic pain and for colds and cough [7] and is used against liver insufficiency [8].

The liver regulates many important metabolic functions. Hepatic injury is associated with distortion of these metabolic functions [9]. Additionally, it is the key organ of metabolism and excretion, thus it is continuously and variedly exposed to xenobiotics because of its strategic placement in the body. The toxins absorbed from the intestinal tract go first to the liver resulting in a variety of liver ailments. Thus liver ailments remain one of the serious health problems. Modern medicines have little to offer for alleviation of hepatic diseases and it is chiefly the plant based preparations which are employed for their treatment of liver disorders. But there are not much drugs available

for the treatment of liver disorders [10,11]. Therefore, many folk remedies from plant origin are evaluated for its possible antioxidant and hepatoprotective effects against different chemical-induced liver damage in experimental animals. CCl₄-induced hepatotoxicity model is frequently used for the investigation of hepatoprotective effects of drugs and plant extracts [12,13].

Roots of *Jurinea dolomiaea* Boiss (Astraceae) are effective in bilious affections as emetic and purgative. Roots are administered internally in leprosy, piles, jaundice. It is active as galactoguge; it is also applied round the eye orbit for night blindness. Root juice is rubbed to soles in burning of the feet and used in liver complaint of childrens.

II. MATERIALS AND METHODS

2.1 Plant material

The plants from which the substances under study were isolated and are traditionally used for the treatment of ulcers, analgesic and liver are the roots of *Jurinea dolomiaea* Boiss. The plant material was collected in the state of Jammu and Kashmir. Plant material was collected from Himalayan region of upper Danchigam and in south Kashmir about 38- 45 meters above the sea level. The plant was identified taxonomically and authenticated at the Herbarium, Department of Botany, and Kashmir University. Plant was washed thoroughly 2 - 3 times with running tap water and then with sterile water followed by shade-dried, powdered and used for extraction.

2.2 Antiulcer activity

Forty albino male rats with a weight of 180–210g were used for the experiment. The rats were fed with standard laboratory before the experiment. The laboratory was windowless with automatic temperature (25 ± 1°C) and lighting controls (14h light/10h dark). Rats were divided into five equal groups (n = 8) and housed in cages. Twenty-four hours before the experiment, the rats were fasted and allowed access to water and libitum.

Anti-ulcerogenic effect of water extract of root was investigated by using the ethanol-induced ulcer model [14]. On the day of the experiment, groups 1, 2 and 3 were injected with 10mg/kg water extract of root, while group 4 was injected with 20mg/kg famotidine and group 5 with saline solution. All of drugs were administered intraperitoneally in 0.5ml vehicle. Following a 30-min-period, all the animals were given 1ml of ethanol (70%) by oral gavages. After one hour the animals were sacrificed by decapitation. The stomach of each was removed, opened and washed with saline solution. For the measurement of the gross gastric mucous, freshly excised

stomach was laid flat and the mucous were traced on clear acetate paper. Gross mucosal lesions were recognized as haemorrhage or linear breaks (erosions) with damage to the mucosal surface. The area of stomach and gross lesions were approximately calculated by planimetry using a simple magnifier. The results were translated to the term of “total ulcer area/total gastric area” and these were expressed as an ulcer index percentage (%).

2.3. Writhing test

All experiments were performed on no-fasted male and female albino Swiss mice weighing 30–38kg. Animals were divided into five equal groups of 6 each. Animals were pretreated with 50, 100 and 200mg/kg doses of water extract of root and 200mg/kg dose of metamizol as reference drug. Control animals received an equal volume of 0.9% NaCl in distilled water. Drugs and saline were given 60min before acetic acid injection. Writhing test was determined according to the method [15]. Writhing was induced by 10mg/kg of intraperitoneally acetic acid (0.6%) injection. Ten millimetres after acetic acid injection, the mice were placed in a transparent box and the number of writhes was counted for period of 10min. Writhing movement was accepted as contraction of the abdominal muscles accompanied by stretching of the hind limbs. Antinociceptive effect was expressed as the reduction of the number of writhing between control and pretreated mice.

$$\text{Percentage reduction of the number of writhing (\%)} = \left[\frac{A_0 - A_1}{A_0} \right] \times 100$$

Where A₀ was the number of writhing of the control, and A₁ was the number of writhing of pretreatment with water extract of root [16].

2.4 Hepatoprotective activity

Wistar albino rats (150-200 g) of either sex were procured from Pharmacy Department of Barkatullah University Bhopal and was used for study. The animals were kept in polypropylene cages and were fed with standard pelleted feed and water ad libitum. The study has got the approval from the Institutional Animal Ethical Committee (IAEC) of Committee for the Purpose of Control and Supervision of Experiments on Animals (CPCSEA).

Analytical Laboratory grade chemicals, solvents were used for the studies, which were procured from s. d. fine and span diagnostic Ltd.

Experimental Animals were divided into five groups, each group containing six animals Group I (normal control) received distilled water for 7 days. Group II (induction control) received CCl₄ 1ml/kg, i. p. 1:1

dilution with coconut oil [17] on 5th day. Group III received liver tonic (5ml/kg, p.o.) for 7 days and CCl₄ induction on 5th day. Groups IV-V, received hydroalcoholic extract of roots (100mg/kg and 200mg/kg p.o) for 7th days and CCl₄ induction on 5th day. On the 8th day, the animals were sacrificed under ether anesthesia, blood and liver samples were collected. The blood was allowed to clot for 30 min; serum was separated by centrifuging and was used for biochemical estimations For histopathological study, liver tissue was quickly removed after autopsy and fixed in 10% formo saline.

The activities of serum glutamate pyruvate transaminase (SGPT) and serum glutamate oxaloacetate transaminase (SGOT) were assessed by the method of Reitman and Frankel. Estimation of serum ALP and serum bilirubin (Jendrassik Groff method) were also carried out to assess the acute hepatic damage caused by CCl₄.

2.5. Statistical analysis

Experimental results concerning this study were mean± S.D. of three parallel measurements. Analysis of variance was performed by ANOVA procedures. Significant differences between means were determined by Duncan's multiple range tests. P values <0.05 were regarded as significant and P values <0.01 very significant.

III. RESULTS AND DISCUSSION

3.1. Effects on acute gastric mucosal lesions induced by ethanol

Ulcer indices (UI) are shown in Table 1. Per-oral administration of 70% ethanol produced multiple mucosal lesions in the rat stomach. Pre-treatment with Water extract of root and famotidine were found to inhibit the ethanol-induced gastric mucosal injury in rats. Preventive effects of 50, 100 and 200mg/kg water extract of root were in a dose-dependent manner (percent inhibitions were 67.7, 61.1 and 77.8, respectively, compared to control) and there was a statistically significance between the effects of used water extract of root doses (P<0.005). Famotidine also significantly inhibited the ethanol-induced gastric lesion (percent decrease was 34.4, compared to ethanol). There were significant differences between all concentrations of water extract of root effects and famotidine effect (P<0.001).

Table 1. The effects of different doses of water extract of root and famotidine on the ethanol induced gastric mucosal injury. Results are expressed by Mean ± S.E.M.

S.No	Groups	Ulcer index (%) (mean±S.E.M.)	Percent decrease of gastric mucosal injury (%)
1	Control	6.70 ± 0.68	–
2	Famotidin 20 (mg/kg)	4.41 ± 0.24*	34.4
3	WER (50mg/kg)	2.20 ± 0.15*	67.7
4	WER(100mg/kg)	2.65 ± 0.26*	61.1
5	WER (200mg/kg)	1.56 ± 0.61*	77.8

3.2. Analgesic effect

Writhing numbers are shown in Table 2. Pretreatment with WER and metamizol were found to inhibit the acetic acid-induced writhing in mice. Inhibitor effects of 50, 100 and 200mg/kg WER were in a dose-dependent manner and significant (percent decrease, compare to control: 62.1, 70.4 and 89.2%, respectively). As seen in Table 2, metamizol also inhibited the acetic acid-induced writhing significantly (P<0.01) (decrease compare to control: 39.4%).

Table 2. Effects of different doses of water extract of root and metamizol on acetic acid-induced writhing in mice. Results are expressed by Mean ± S.E.M.

S.No	Groups	Writhing number (mean±S.E.M.)	Percent decrease of acetic acid-induced writhing in mice (%)
1	Control	25.3 ± 2.3	–
2	Metamizol (200mg/kg)	16.3 ± 2.6*	40.5
3	WER (25mg/kg)	8.5 ± 3.8*	63.4
4	WER(50mg/kg)	3.8 ± 2.9*	72.1
5	WER (100mg/kg)	9.5 ± 1.4*	90.3

3.3. Hepatoprotective Activity

The hepatic injury induced by CCl₄ caused significant rise in marker enzymes SGOT, SGPT, ALP and total bilirubin. The serum enzymes like SGOT, SGPT, ALP and total bilirubin of treated animals were significantly reduced ($p < 0.01$) by seven days pretreatment of hydroalcoholic extract of roots of

Jurinea dolomiaea at two dose levels 100mg/kg and 200mg/kg, when compared with CCl₄ treated control (group II). From the result it is clear that the drugs show dose dependent activity. The effects on serum marker enzymes and total bilirubin are shown in Table 3.

Table No. 3: Effect of Hydroalcoholic Extract of *Jurinea dolomiaea* Boiss root on Serum Enzymes and Total Billirubin.

Results are expressed as mean \pm SD.

Groups	SGOT IU/L	SGPT IU/L	Alkaline phosphatase (U/L)	Total Billirubin mg/dl
Group I (Normal control)	57.37 \pm 2.53	39.65 \pm 6.4	167.33 \pm 5.15	0.95 \pm 0.16
Group II (CCl ₄ treated control)	166.36 \pm 4.20	109.34 \pm 7.5	298.50 \pm 1.36	1.86 \pm 0.28
Group III (CCl ₄ + Liver Tonic)	62.58 \pm 3.88	57.50 \pm 5.55	208.33 \pm 4.49	0.86 \pm 0.12
Group IV (CCl ₄ + hydroalcoholic extract of <i>J.dolomiaea</i> roots 100mg/kg)	70.66 \pm 3.89	52.54 \pm 4.28	197.53 \pm 6.55	0.95 \pm 0.15
Group V (CCl ₄ + hydroalcoholic extract of <i>J.dolomiaea</i> roots 200mg/kg)	64.36 \pm 3.99	59.50 \pm 6.59	190.55 \pm 4.45	0.89 \pm 0.20

Light Microscopic Examination

Carbon tetrachloride (CCl₄) cause marked damage of rat hepatocytes in the form of fatty degeneration, cytoplasmic vacuolation, focal and confluent hepatocellular necrosis and portal tract fibrosis with endothelial swelling and disruption (Fig 2). Pretreatment with hydroalcoholic extract of *Jurinea dolomiaea* root at two dose level markedly attenuated the CCl₄ induced histopathological changes in rat liver (fig. 4 and 5).

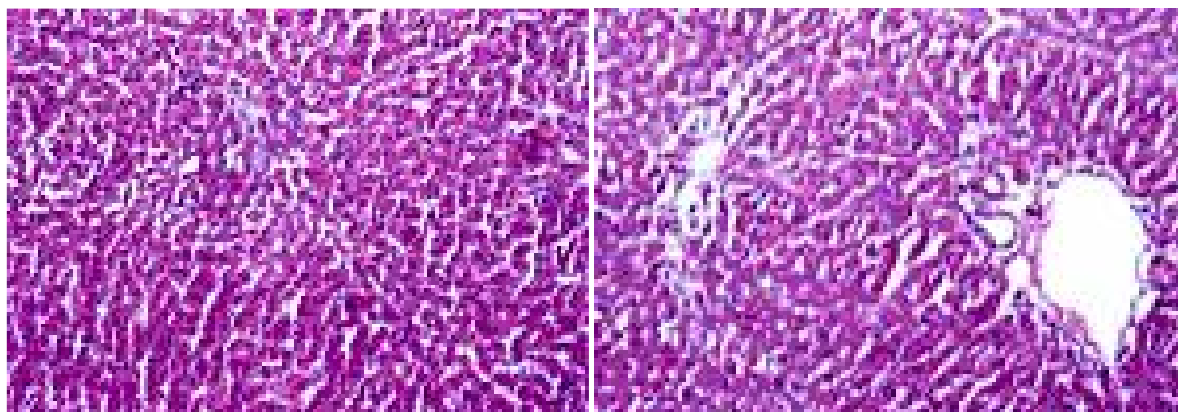


Fig.1 Control

Fig.2 Toxicant

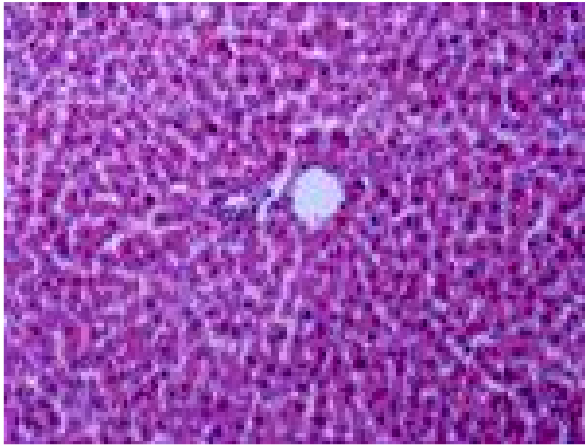
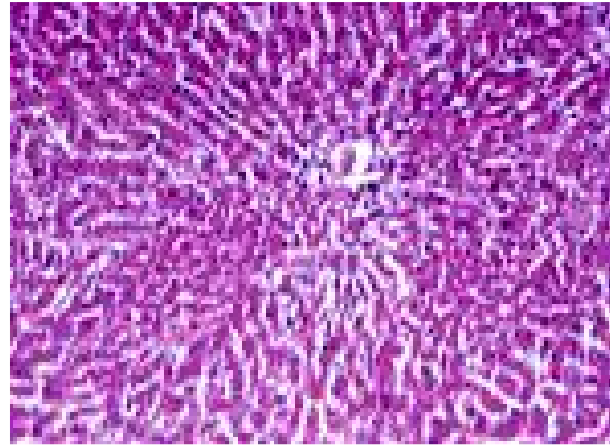
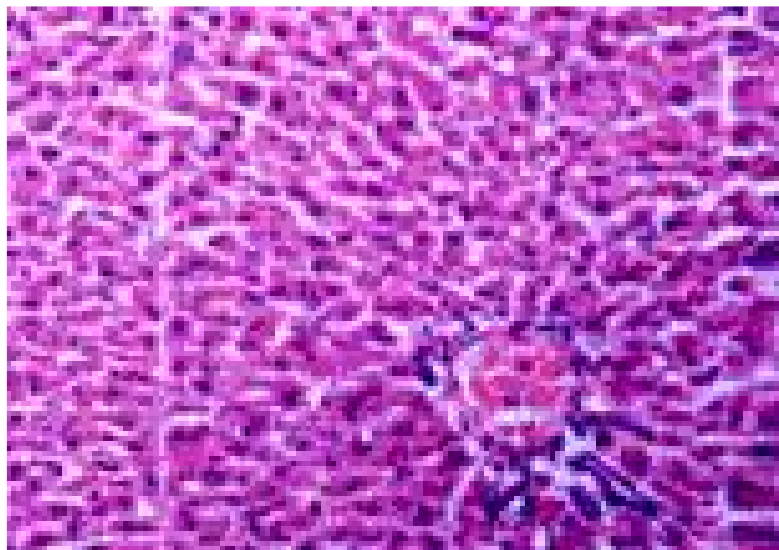


Fig.3 Standard

Fig.4 H. E. of *J dolomiaea* roots (100mg/kg)Fig.5 H. E. of *J dolomiaea* roots (200mg/kg)

IV. DISCUSSION

The roots of plant was reported as anti-inflammatory and antirheumatic effects [18, 19], acute diuretic, natriuretic and hypertensive effects [20], cardiovascular effects [21] and stimulation of proliferation of human lymphocytes [22]. The effects of the roots are also used in the therapy of prostatic hyperplasia [23, 24, 25]. Moreover, this plant has been used in the traditional therapy of hypertension [26]. On the basis of the results of this study, it is clearly indicated that water extract of roots has a powerful effect on antiulcer activity against ethanol-induced ulcerogenesis and analgesic effect on acetic acid-induced stretching and it can be used for therapy of ulcerogenesis and gastric mucosal injury. Since the changes associated with CCl₄-induced liver damage are similar to that of acute viral hepatitis[27]. The hepatotoxicity induced by CCl₄ is due to its metabolite CCl₃•, a free radical that alkylates cellular proteins and other

macromolecules with a simultaneous attack on lipids, in the presence of oxygen, to produce lipid peroxides, leading to liver damage[28]. Amino transferases are present in high concentration in liver linking carbohydrate and amino acid metabolism. Alanine amino transferase and aspartate amino transferase are well known diagnostic indicators of liver disease. In cases of liver damage with hepatocellular lesions and parenchymal cell necrosis, these marker enzymes are released from the damaged tissues into the blood stream[29]. Alkaline phosphatase is a membrane bound enzyme and its elevations in plasma indicate membrane disruption in the organ. The level of this enzyme increases in cholestasis[30]. Hepatotoxicity is characterized by cirrhotic liver condition which increases the bilirubin release[31]. The total bilirubin were found to increase in the hepatotoxic animals[32] and were significantly reduced in groups of

hydroalcoholic root extract of *Jurinea dolomiaea* administered rats as compared to that of toxicant rats. The effect was more pronounced with these extracts, this might be due to the higher contents of flavonoids. It is due to the reducing accumulation of toxic CCl₃ derived metabolites, which may contribute to the changes in the rough endoplasmic reticulum and the disturbance of protein metabolism in liver.

Comparative histopathological study of the liver from different groups of rats corroborated the hepatoprotective efficacy of hydroalcoholic root extract of *Jurinea dolomiaea* (fig. 1 to 5). Various pathological changes like steatosis, centrilobular necrosis and vacuolization seen in group II (toxicant rats) is due to oxidative damage by free radical generation. These pathological changes were prevented to moderate extent in both test groups. This might be due to presence of flavonoids and ascorbic acid.

V. CONCLUSION

On the basis of the results of this study, it is clearly indicated that water extract of root has a powerful antiulcer, analgesic and hepatoprotective activity in pharmaceutical industry. Some studies have revealed that the antioxidants melatonin and carotene potentiate the antinociceptive responses. It was indicated that vitamin E has beneficial effects in improvement of rheumatic disease, intermittent claudication or angina pectoris. Thus the water extract of root has effective antiulcer activity against ethanol-induced ulcerogenesis and analgesic effect on acetic acid-induced stretching and it can be used for therapy of ulcerogenesis and gastric mucosal injury. The activities of the enzymes i.e. total bilirubin were found to increase in the hepatotoxic animals and were significantly reduced in groups of hydroalcoholic extract of roots of *Jurinea dolomiaea* administered rats as compared to that of toxicant rats.

ACKNOWLEDGEMENTS

The authors acknowledge Department of Chemistry, Govt. Geetanjali Girl's (Autonomous) P.G. College, Berasiya road Bhopal – 462038, Madhya Pradesh (India), Pharmacy Department of Barkatullah University Bhopal Madhya Pradesh (India), and Department of Chemistry, Maulana Azad College of Arts, Science & Commerce, Aurangabad Maharashtra (India) for providing necessary facilities during the study.

REFERENCES

- [1] Yagi, K., 1987. Lipid peroxides and human disease. *Chemistry and Physics of Lipids* 45, 337–341.
- [2] Halliwell, B., Gutteridge, J.M.C., 1985. *Free Radicals in Biology and Medicine*. Oxford University Press, Oxford, UK.
- [3] Ho, C.T., Ferraro, T., Chen, Q., Rosen, R.T., 1994. Phytochemical in teas and rosemary and their cancer-preventive properties. In: Ho, C.T., Osawa, T., Huang, M.T., Rosen, R.T. (Eds.), *Food Phytochemicals for Cancer Prevention. II. Tea, Spices and Herbs*. ACS Symposium Series 547, American Chemical Society, Washington, DC, pp. 2–9.
- [4] Grice, H.C., 1986. Safety evaluation of butylated hydroxyl toluene (BHT) in the liver, lung and gastrointestinal tract. *Food Chemistry and Toxicology* 24, 1127–1130.
- [5] Wichi, H.P., 1988. Enhanced tumour development by butylated hydroxyanisole (BHA) from the prospective of effect on forestomach and oesophageal squamous epithelium. *Food Chemistry and Toxicology* 26, 717–723.
- [6] Yesilada, E., Sezik, E., Honda, G., Takaishi, Y., Takeda, Y., Tanaka, T., 2001. Traditional medicine in Turkey X. Folk medicine in Central Anatolia. *Journal of Ethnopharmacology* 75, 95–115.
- [7] Sezik, E., Yesilada, F., Tabata, M., Honda, G., Takaishi, Y., Fujita, T., Tanaka, T., Takeda, Y., 1997. Traditional medicine in Turkey VIII. Folk medicine in East Anatolia Erzurum Erzincan Ağrı, Kars, Iğdır provinces. *Economic Botany* 51, 195–211.
- [8] Yesilada, E., Honda, G., Sezik, E., Tabata, M., Goto, K., Ikeshiro, Y., 1993. Traditional medicine in Turkey IV. Folk medicine in the Mediterranean subdivision. *Journal of Ethnopharmacology* 39, 31–38.
- [9] Wolf, P.L. Biochemical diagnosis of liver diseases. *Indian Journal of Clinical Biochemistry* 1999. 14, 59–90.
- [10] Karan, M., Vasisht, K., Handa, S.S. Antihepatotoxic activity of *Swertia chirata* on carbon tetrachloride induced hepatotoxicity in rats. *Phytotherapy Research*. 1999. 13, 24–30.
- [11] Chatterjee, T.K., *Medicinal Plants with Hepatoprotective Properties*. Herbal Options. Books and Applied Allied (P) Ltd., Calcutta, 2000. 143.
- [12] Rubinstein, D. Epinephrine release and liver glycogen levels after carbon tetrachloride administration. *American Journal of Physiology*, 1962. 203, 1033–1037.
- [13] Suja, S.R., Latha, P.G., Pushpangadan, P., Rajasekharan, S., Aphrodisiac property of *Helminthostachys zeylanica* in mice. *Journal of Tropical Medicinal Plants* 2002. 3, 191–195. 6.
- [14] Büyükköroğlu, M.E., Taysi, S., Polat, F., Göçer, F., 2002. Mechanism of the beneficial effects of dantrolene sodium on the ethanol-induced acute gastric mucosal injury in rats. *Pharmacological Research* 45, 421–424.
- [15] Zakaria, M.N.M., Zathakrishnan, R., Chen, H.B., Kamil, M., Algisri, A.N., Chan, K., Al-attas, A., 2001. Antinociceptive and antiinflammatory properties of *Carraluma arabica*. *Journal of Ethnopharmacology* 76, 155–158.
- [16] Gülçin, I., Büyükköroğlu, M.F., Oktay, M., Küfrevioğlu, Ö.İ., 2003d. Antioxidant and analgesic activities of

- turpentine of *Pinus nigra* arn. subsp. *palisiana* (Lamb.) Holmboe. *Journal of Ethnopharmacology* 86, 51–58.
- [17] Lin, C.C., Yen, M.H., Lo, T.S., Lin, J.M., Evaluation of the hepatoprotective and antioxidant activity of *Boehmeria nivea* var. *nivea* and *B. nivea* var. *tenacissima*. *J. Ethnopharmacol.* 1998, 60, 9–17.
- [18] Obertreis, B., Giller, K., Teucher, T., Behnke, B., Schmitz, H., 1996. Anti-inflammatory effect of *Urtica dioica* folia extract in comparison to caffeic malic acid. *Arzneimittel Forschung Research* 46, 52–56.
- [19] Riehemann, K., Behnke, B., Schulze-Osthof, K., 1999. Plant extracts from stinging nettle (*Urtica dioica*), an antirheumatic remedy, inhibit the proinflammatory transcription factor NF- κ B. *FEBS Letters* 442, 89–94.
- [20] Tahri, A., Yamani, S., Legssyer, A., Aziz, M., Mekhfi, H., Bnouham, M., Ziyat, A., 2000. Acute diuretic, natriuretic and hypotensive effects of a continuous perfusion of aqueous extract of *Urtica dioica* in the rat. *Journal of Ethnopharmacology* 73, 95–100.
- [21] Lara Testai^a, Silvio Chericoni^b, Vincenzo Calderone^a, Giulia Nencioni^b, Paola Nieri^a, Ivano Morelli^b, Enrica Martinotti^a (2002). Cardiovascular effects of *Urtica dioica* L. (Urticaceae) roots extracts: in vitro and in vivo pharmacological studies. *Journal of Ethnopharmacology* .pp105-109.
- [22] Wagner, H., Willer, F., Kreher, B., 1989. Biologically active compounds from the aqueous extract of *Urtica dioica*. *Planta Medica* 55, 452–454.
- [23] Krzeski, T., Kazon, M., Borkowski, A., Kuczera, J., 1993. Combined extracts of *Urtica dioica* and *Pygeum africanum* in the treatment of benign hyperplasia: double-blind comparison of two doses. *Clinical Therapy* 6, 1011–1020.
- [24] Hiramoto, T., Homma, M., Oka, K., 1994. Effect of stinging nettle extracts and their steroidal components on the Na⁺,K⁺-ATPase of the benign prostatic hyperplasia. *Planta Medica* 60, 30–33.
- [25] Lichius, J.J., Muth, C., 1997. The inhibiting effect of *Urtica dioica* root extracts on experimentally induced prostatic hyperplasia in the mouse. *Planta Medica* 63, 307–310.
- [26] Ziyat, A., Legssyer, A., Mekhfi, H., Dassouli, A., Serhrouchni, M., Benjelloun, W., 1997. Phytotherapy of hypertension and diabetes in oriental Morocco. *Journal of Ethnopharmacology* 58, 45–54.
- [27] Suja, S.R., Latha, P.G., Pushpangadan, P., Rajasekharan, S., Evaluation of hepatoprotective effects of *Helminthostachys Zeylanica* (L.) Hook against carbon tetrachloride induced liver damage in Wistar rats. *J. Ethnopharmacol.* 2004, 92, 61–66.
- [28] Bishayee, A., Sarkar, A., Chatterjee, M., The hepatoprotective activity of Carrot (*Daucus carota* L) against carbon tetrachloride intoxication in mouse liver. *J. Ethnopharmacol.* 1995, 47, 69–74.
- [29] Sethumadhavan, S., Theruvathil, S., Rangaswamy, A., Hepatoprotective activity of chitosan against isoniazid and rifampicin-induced toxicity in experimental rats *European J. Pharmacol.* Xx, 2007, xxx-xxx.
- [30] Sanmugopriya, E., Venkataraman, S., Studies on hepatoprotective and antioxidant actions of *Strychnos potatorum* Linn. Seeds on CCl₄-induced acute hepatic injury in experimental rats *J. Ethnopharmacol.*, 2006. (105). 154–160.
- [31] Man-Fung, Y., Takanobu, K., Masashi, M., Annie On-On, C., John, C.H.Y., He-Jun, Y., Am. Clinical outcome and virologic profiles of severe hepatitis B exacerbation due to YMDD mutations. *J. Hepatol.* 2003, (39)850–855.
- [32] Deepa, P.R., Varalakshmi, P., Protective effect of low molecular weight heparin on oxidative injury and cellular abnormalities in Adriamycin induced cardiac and hepatic toxicity. *Chem. Biol. Interact.* 2003, (146), 201–210.