

# Arteries of Pelvic member in Tucanuçu (*Ramphastos toco albogularis* – Cabanis , 1862)

Ludmila Angélica da Fonseca<sup>1</sup>, Roseâmely Angélica de Carvalho Barros<sup>2</sup>,  
Thiago Sardinha de Oliveira<sup>3</sup>, Zenon Silva<sup>2</sup>, Lázaro Antônio dos Santos<sup>1</sup>,  
Lucas de Assis Ribeiro<sup>1</sup>, Frederico Ozanam Carneiro e Silva<sup>1</sup>

<sup>1</sup>Laboratory of animal anatomy, Federal University of Uberlândia, Campus Umuarama, Avenida Mato Grosso, Uberlândia, Minas Gerais.

<sup>2</sup>Laboratory of Comparative Anatomy, Federal University of Goiás – Regional Catalão – Rua Terezinha Margon Vaz, s/n, Residencial Barka II, 75706-881, Catalão-GO.

<sup>3</sup>Faculty of Biological and Health Sciences, Department of Pharmacy, Federal University of Vales do Jequitinhonha e Mucuri, MGT 367 - Km 583, nº 5000 Alto da Jacuba, 39100-000, Diamantina, Minas Gerais, Brazil.

**Abstract**— This study is an anatomic description of pelvic limb vascularization of Tucanuçu (*Ramphastos toco albogularis*). For this, 8 specimens donated by “Centro de Triagem de Animais Silvestres de Catalão – CETAS” were used. In four specimens, arterial system was injected with latex art red stained glue and dissected. Another four, arterial system was injected with vinyl acetate (vinilite) and subjected to corrosion in nitric acid, resulting molds for analyse and description. Results were compared with pertinent citations in domestic birds, compiled from classical works of veterinary anatomy. The project was approved by ethical committee in animal experimentation of Federal University of Uberlândia (CEUA/UFU) under number 067/12. The present work work shows unprecedentedly discovered about Tucanuçu, indicating basic arterial pattern of pelvic limb and showing similarities to domestic birds, however, slight differences may be noted, especially regarding the describe arterial branches in domestic birds that are not present in Tucanuçu.

**Keywords**— Circulatory System; Arteries; Wild Animals; Toucan.

## I. INTRODUCTION

Studies applied in animal anatomy are essential for descriptions, comparisons and preservation of species, especially when comes to wild animals. In addition, these studies help clinical diagnoses, treatment and surgical approaches for veterinary medicine [1].

Tucanuçu, also known as Toco Toucan (*Ramphastos toco albogularis*), has specific characteristics such huge orange beak with a black spot on the end, black plumage on back and belly, around the eyes there is a border of bare yellow skin. The eyelids are blue, crop is white and plumage under tail is reddish. It is included in Piciformes order and belongs Ramphastidae family [2,3], is not in extinction and is considered the largest species among members of family [18, 4]. Tucanuçu can measure 56 centimeters in length and can weigh 540 grams [5]. Despite its size, beak is very light due to its internal cavity structure, which is used as food capture instrument [6, 7]. Using its beak end, as were tweezers, Tucanuçu capture small fruits and other foods, throwing them upwards, opening its beak and swallowing [7].

According to Fecchio (2011), Tucanuçu has a wide distribution in brazilian territory, where is a typical inhabitant of fields and more forested areas in east, southeast and south of Brazil, as well Paraguay, Bolivia and Argentina northern. It is a bird of exotic and rare beauty and ends up being desired by many people and being an animal linked to traffic of wild animals [9].

According to Castro et al. (2002), ranfastids are classified as canopy frugivores, but complement diets with eggs and chicks of other birds or small vertebrates [10, 11, 12].

As they are large birds, Tucanuçu explore vast territories, covering great distances in food search, a behavior that is intensified in dry seasons [15]. In tropical forests, the most important dispersion syndrome is zoocoria, when seeds of nearly 75% of plant species have seeds dispersed, very important factor for forest regeneration and 20 - 50 % diet of birds and mammals [13, 14].

*Ramphastos toco albogularis* is considered a typical example of avian diversity in South American

continent. However, may come to threatened, mainly by human actions, including trafficking of wild animals that ends in death of many specimens [12, 16, 17]. Furthermore besides Tucanuçu is not included in red list of endangered species, is know that diseases, of most varied etiologies and anthropic actions on environment have severely affected brazilian wild fauna, causing mortality rates wild birds, including Tucanuçu [18, 19].

On the other hand, knowledge of circulatory system anatomy in wild animals has been sought by scientists from all world, dealing organs or specific segments of the body. In this sense descriptive anatomical studies of species are essential to acquire data on its biology and importance for ecosystem. To date, there is a great lack of studies on arterial vascularization of Tucanuçu (*Ramphastos toco albogularis*) [12].

Thus, taking into account the importance of circulatory system, this study aimed investigate and describe arteries of pelvic limb of Tucanuçu (*Ramphastos toco albogularis* - Cabanis, 1862) in order to provide different areas grounds of knowledge, contribute as support for actions in programas of species preservation and contribute with diagnoses, clinical and surgical conduct applied in veterinary medicine.

## II. METHODS

This study is an anatomic description of aorta caudal part orientate to pelvic limb vascularization of Tucanuçu (*Ramphastos toco albogularis*). For this, 8 adult specimens with no defined age, donated by “Centro de Triagem de Animais Silvestres de Catalão – CETAS”, were used. Considering descriptive approach of this work, statistical analysis is not necessary. All procedures were conducted in accordance with ethical principles and were approved by the Institutional Ethics in Research Committee at the Federal University of Uberlândia (CEUA/UFU nº 067/12).

The specimens were plucked in boiling water and then, in four specimens the arterial system was dissected and inject with Latex Artecola, colored with red pigment Wandalor through aortic arch or sciatic artery in abdominal cavity. Behind three hours, was made a fixation with aqueous 10 % formaldehyde solution to conservation, staying for one week. Another four, arterial system was injected with vinyl acetate (vinilite) and after 12 hours was subjected to corrosion in 30% nitric acid aqueous solution, resulting molds for analyse and description

The preparation of anatomical pieces was performed under consecrated techniques in macroscopic

anatomy and description nomenclature adopted is according the Handbook of Avian Anatomy: Nomina Anatomica Avium (1993) and/or Nickel, Shummer, Seiferle (1977) [21, 22]. The Cyber Shot 7.2 megapixels digital camera was used to photographical documentation.

## III. RESULTS

The blood supply to pelvic member of Tucanuçu is charge of two major arteries, branches of Abdominal Part of Aorta: *External Iliac Artery and Sciatic Artery*.

**External Iliac Artery** - The first major branch of aorta. Contributes to supply pelvic limb, however, is not exclusive to limb and supplies other regions. Arises from lateral face of aorta, caudally to origin of Cranial mesenteric a., next to ventral face of Synsacrum, runs laterally, crossing kidney, in the space between middle and cranial renal lobe. Along its path, through kidney, it does not emit any collateral branch, either to kidney or other tissues, although has an intimate relationship with it and lumbar plexus, which is located ventrally. After leaving lateral border of kidney middle lobe, the *External Iliac A.* emits two branches: one caudal branch, is *Pubic Artery* and other cranial, the *Deep Iliac Circumflex* (Figure 1-c, e).

The *Pubic A.* borns through caudal surface of *External Iliac A.*, follows in a caudal direction, close to lateral edge of Synsacrum Bone, providing branches for caudolateral part of abdominal wall. The cranial branch is *Deep Iliac Circumflex A.*. In turn, divides into several branches destined to caudal part of chest and cranial wall of abdomen. Continuation of *External Iliac* is *Femoral A.*. It goes in a lateral direction, close to lateral edge of Synsacrum Bone, penetrating the posterior thigh muscles. It perforates posterior thigh muscle group and already on lateral part, it crosses ventrally, from cranial to caudal, to *Ischiatic A.*, ending in caudolateral muscles of thigh and gluteal region.

**Sciatic Artery** - The largest branch of aorta. Arises from lateral surface of aorta and becomes caudolateral, between middle and caudal lobes of kidney. Along kidney emits branches to caudal lobe and eventually, to middle lobe. When leaving pelvic cavity crossing to dorsal face of synsacrum, in lateral direction, emits *Obturator A.*, which crosses obturated foramen, from dorsolateral to ventromedial, together internal obturator m., which supplies branches and iliac muscle. This path emits *Gluteal A.*, destined to muscles of gluteal region.

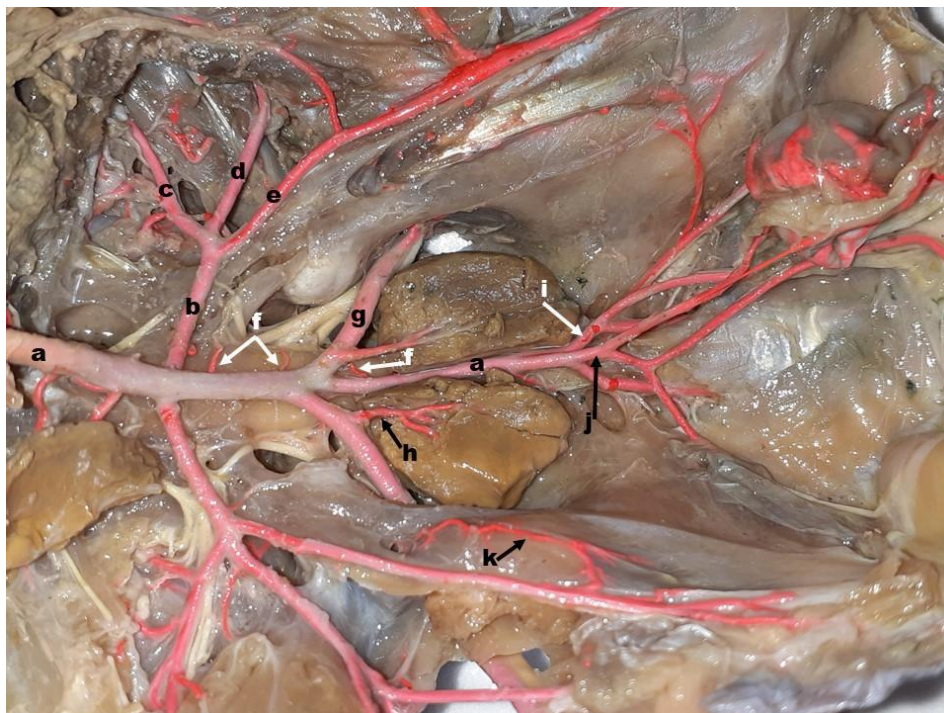

Fig.1- Ventral view of abdomino-pelvic cavity of Tucanuçu (*Ramphastos toco albogularis*) - Branches of aorta; b- external iliac A.; c- deep iliac circumflex A.; d- femoral A.; e- pubic A.; f- sacral A.; g- ischial A.; h- caudal renal A.; i- internal iliac A.; j- caudal mesenteric A.; k- obturator A..

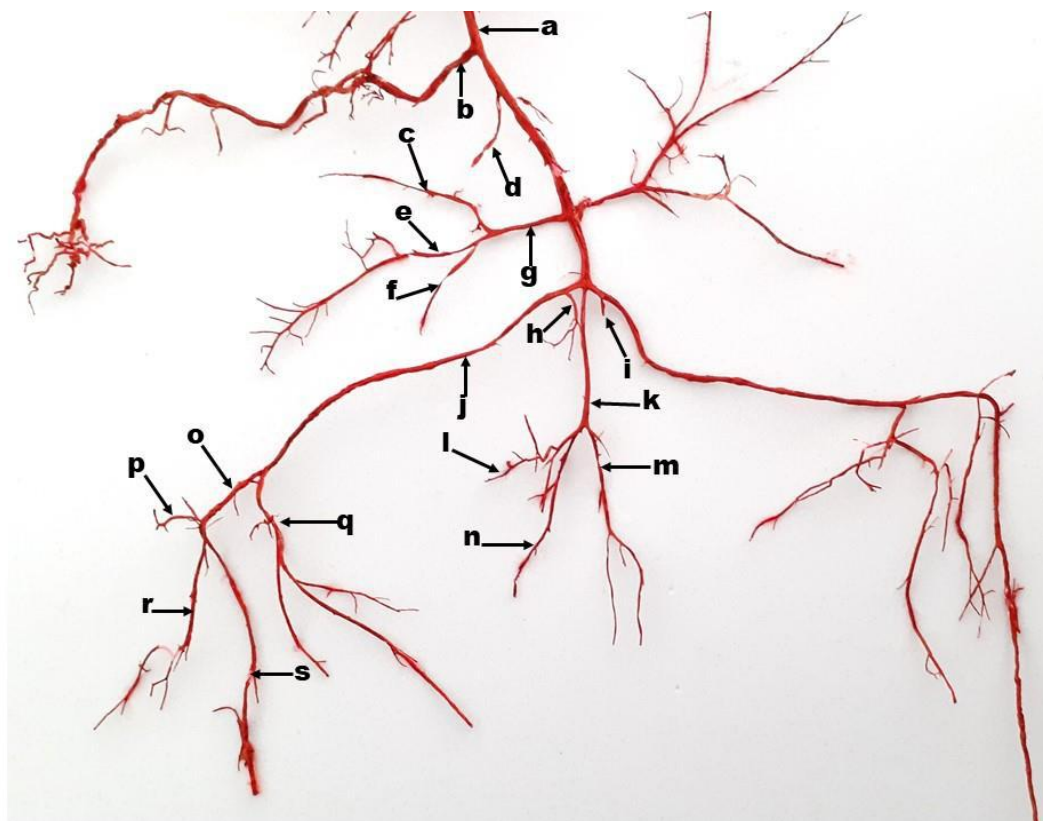


Fig.2- Vascular mold abdomino-pelvic region of Tucanuçu (*Ramphastos toco albogularis*): a- aorta; b- celiac A.; c- deep iliac circumflex A.; d- cranial mesenteric A.; e- femoral A.; f- pubic A.; g- external iliac A.; h- right caudal renal A.; i- left caudal renal A.; j- ischial A.; k- sacral part of aorta; l- caudal mesenteric A.; m- left internal iliac A.; n- right internal iliac A.; o- poplítea A.; p- genicular middle A.; q- crural A.; r- tibial caudal A.; s- cranial tibial A..

After leaving pelvis, *Ischiatica A.* follows deeply lateral thigh muscles, up popliteal fossa, always closely to caudal proximity with homonymous nerve and cranially to homonymous vein.

After crossing almost entire length of thigh, without emitting any branches, *Ischiatic A.* enters popliteal fossa and is named *Popliteal A.* The first branch of *Popliteal A.* borns caudally, is *Sural Caudal A.* (Deep Femoral), whose distribution occurs in superficial caudal muscles of leg. Next, a smaller artery born in the same sense, is *Sural Cranial A.*, whose branching occurs in deep sural muscles. A muscular branch, destined for lateral distal region of thigh borns from *Sural A.*.

*Poplitea A.* continues its path to caudal face of Tibiotarso bone, where emits *Caudal Genicular A.* Follows distally a short distance, bending sharply, in distal direction as a single *Tibial A.*, in most cases, but in two cases (20%), it divides into *Tibial Cranial A.* and *Tibial*

*Caudal A.* Both tibial arteries run distally, inside anterolateral muscles of tibia. The *Tibial A.* reaches Tibiotarsometatarsal articulation, supplying posterior leg muscles, while cranial tibial goes to the foot.

*Tibial Cranial A.* emits a branch cranially, the *Genicular A.*, and crosses leg bones, in craniocaudal direction, passes in a space between tibia and fibula, which is not completely merged, enters fascial compartment craniolateral of leg, crossing it, from proximal to distal, between anterolateral muscles of leg, descends in Tibiotarsian region, up to ankle. At this point, crosses cranial face of Tibiotarso-tarsus-metatarsal joint, caudally to retinaculum of cranial tibial m. and medially to tendon. From this point, cranial face of Tarsometatarsal bone gains, following *Tarsometatarsiana A.* until Tarsometatarsophalangeal articulation, emitting a branch medially, destined to sole of the foot and a lateral branch that divides to caudal toe and toe side. Then emits a branch to medial finger following as *Digital Middle A.* middle for homonymous finger.

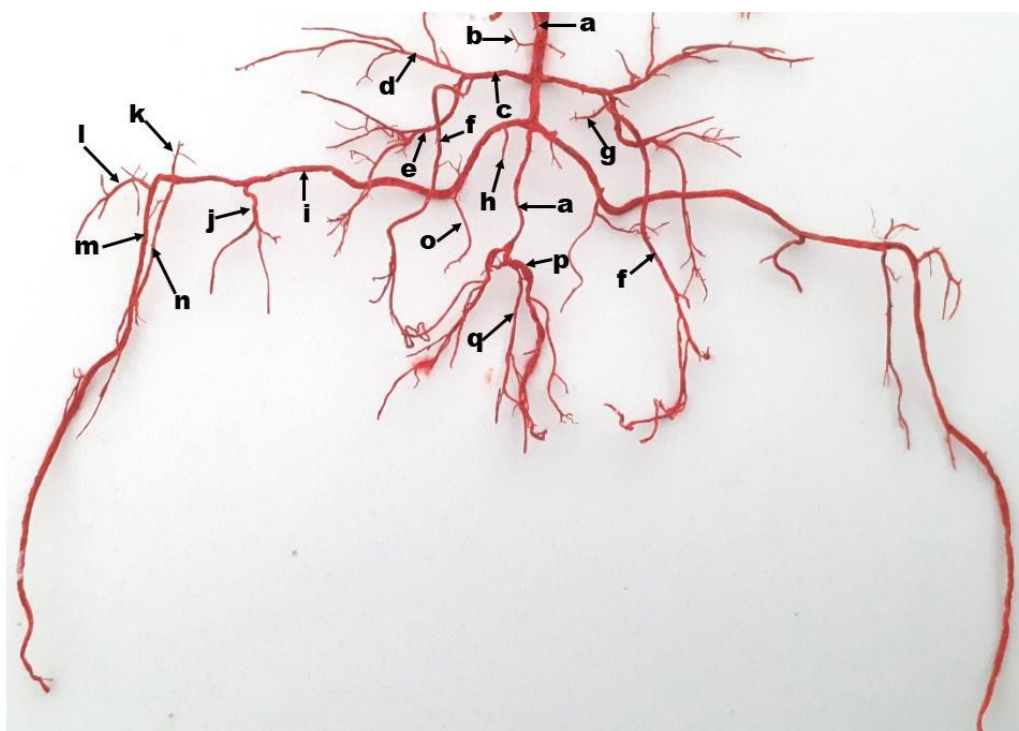


Fig.3- Vascular mold of abdomino-pelvic region of Tucanuçu (*Ramphastos toco albogularis*): a- aorta; b- cranial renal A.; c- external iliac A.; d- deep iliac circumflex A.; e- pubic A.; f- femoral A.; g- renal middle A.; h- right caudal renal A.; i- ischial A.; j- crural A.; k- cranial genicular A.; l- genicular middle; m- cranial tibial A.; n- tibial caudal A.; o- obturator A.; p- internal iliac A.; q- caudal mesenteric A..

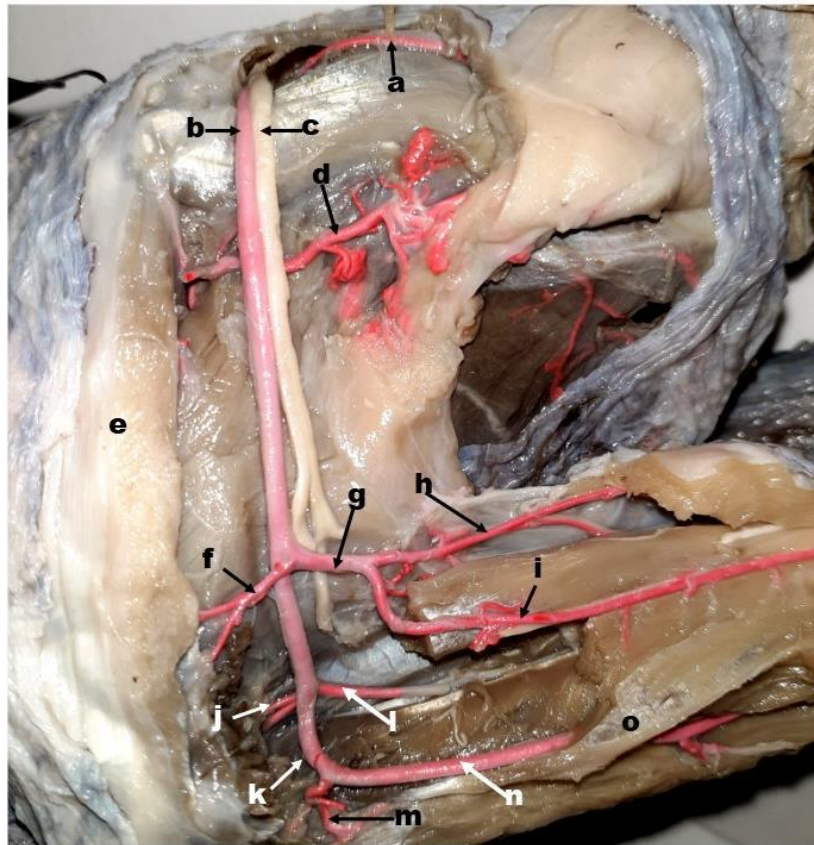


Fig.4- Arterial vascularization of thigh and leg in Tucanuçu (*Ramphastos toco albogularis*): a- gluteal A.; b- ischial A.; c- sciatic n.; d- femoral A.; e- Cranial femorals mm.; f- cranial genicular A.; g- crural A.; h- crural caudal A.; i- cranial crural A.; j- genicular middle A.; k- popliteal A.; l- tibial caudal A.; m- caudal genicular A.; n- cranial tibial A.; o- tibial bone.

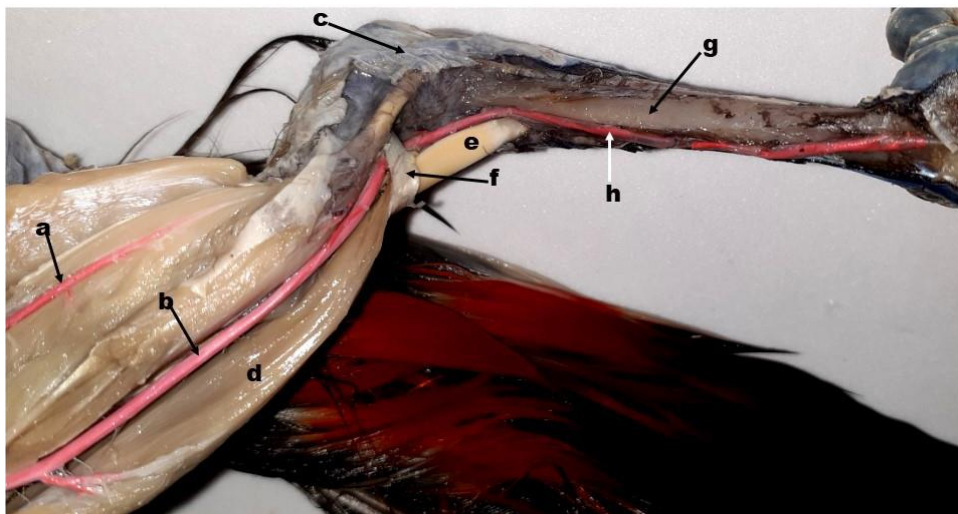


Fig.5- Arterial vascularization of leg in Tucanuçu (*Ramphastos toco albogularis*): a- tibial caudal A.; b- cranial tibial A.; c- tibiotarsometatarsal articulation; d- cranial tibial m. (folded); e- tendon of cranial tibial m.; f- retinaculum of cranial tibial .; g- metatarsal bone; h- metatarsian A..

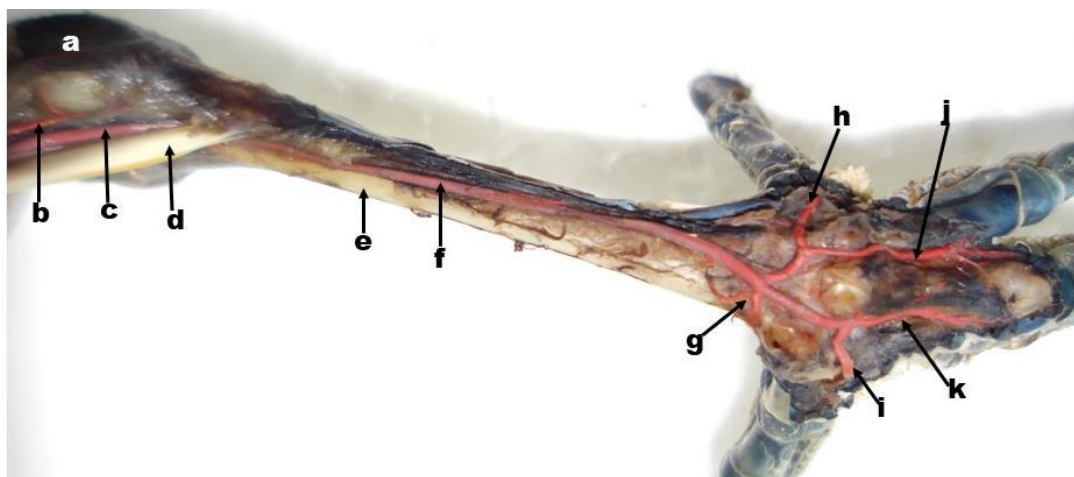


Fig.6- Arterial vascularization of Tarsometatarsus and stump foot in Tucanuçu (*Ramphastos toco albogularis*): a- tibiotarsometatarsal articulation; b- tibiotarsometatarsal network; c- cranial tibial A.; d- tendon of cranial tibial m.; e- metatarsal bone; f- metatarsal A.; g- plant A.; h- digital IV A.; i- digital I A.; j- digital III A.; k- digital II A..

#### IV. DISCUSSION

Specific literature on circulatory system of birds is scarce and sometimes inconsistent. Thus, relevant citations are limited to Nickel; Schummer; Seiferle (1977) and Baumel in Sisson; Grossman (2008), beyond include citations from other authors, in books and treatises on Veterinary Anatomy, which are repetitive and related to referred authors. Therefore, this present paper discussion is limited to these [22, 23].

According to Nickel; Schummer; Seiferle (1977), pelvic limb of birds is supplied with blood from *External Iliac* and *Ischial Aa.*, in agreement with the findings in Tucanuçu. Baumel in Sisson; Grossman (2008) states that blood supply to pelvic limb of birds is guaranteed by the last branches of abdominal part of aorta, constituting *External* and *Ischial Iliac Aa.* Our observations in Tucanuçu reveal these same vessels, however, they are not the last branches of aorta [22, 23].

Nickel; Schummer; Seiferle (1977) and Baumel in Sisson; Grossman (2008) state do not have a *common iliac artery*, in agreement with observations in Tucanuçu. For Baumel in Sisson; Grossman (2008), the first large blood vessel for pelvic limb is *External Iliac A.*, which arises from lateral aspect of aorta, caudally to origin of *Cranial Mesenteric A.*, runs laterally between cranial and middle lobes of kidney, without emitting any branches in this path. Nickel; Schummer; Seiferle (1977) cites an origin at level of Sincracó ventral surface. In Tucanuçu, with regard to referred vessels, the findings are in agreement with the referred Authors [22, 23].

The first branch of *External Iliac A.*, is *Femur Circumflex A.*, whose origin occurs at hip articulation level,

proceeding distally to cranial surface of thigh, supplying extensor muscles and knee articulation (NICKEL; SCHUMMER; SEIFERLE, 1977). Baumel in Sisson; Grossman (2008) states, already pelvic wall, *External Iliac A.*, caudally, emits *Pubic A.* or *Internal Pelvic A.*, which supplies abdominal wall and peritoneum. In Tucanuçu, after leaving lateral edge of kidney, *External Iliac A.* emits a caudal branch, *Pubic A.*, which runs caudally and close to edge of sinsacral bone, providing branches for abdominal wall. At the same time *Deep Iliac Circumflex A.* borns cranially, bound for caudal region of chest and cranial wall of abdomen [22, 23].

Nickel; Schummer; Seiferle (1977) do not comment about *pubic a.*, but indicate a compatible artery, which was called *pelvic a.*, since its origin and path are similar, while Baumel in Sisson; Grossman (2008) do not comment [22, 23].

According to Nickel; Schummer; Seiferle (1977) *femoral a.* down to Knee flexors mm. where becomes *genicular a.* Baumel in Sisson; Grossman (2008) states that *femoral a.* is the continuation of *external iliac artery a.* It branches in ventrolateral wall of abdomen, pre-acetabular region and cranio-lateral region of thigh. The observations in Tucanuçu are partially in agreement with Baumel in Sisson; Grossman (2008), since *femoral a.* is the middle branch of *external iliac a.*, course which runs sideways along edge of sinsacral bone to posterior thigh muscles, already lateral face, ventrally crosses *aciatic a.* from cranial to caudal, ending in the caudolateral muscles of thigh and gluteal region [22, 23].

Still in according to Baumel in Sisson; Grossman (2008), *femoral a.* emits *circumflex of thigh a.*, emitting

*cranial femoral a.* that supplies cranio-proximal region of thigh. Nickel; Schummer; Seiferle (1977) do not mention this branch from *femoral a.*, neither is not present in Tucanuçu [23, 22].

*Ischiatic a.* in birds, according to Nickel; Schummer; Seiferle (1977), and Baumel in Sisson; Grossman (2008), originates from aorta, at level of hip articulation and traject between lower and middle lobes of kidney, considering the main artery of pelvic limb of birds, in accordance with the findings in Tucanuçu [22, 23].

Still inside *pelvis a.*, the *ischiatic a.* emits branches to middle and caudal lobes of kidney and leaves pelvic cavity through sciatic foramen in company of eponymous nerve (NICKEL; SCHUMMER; SEIFERLE, 1977; BAUMEL in SISSON; GROSSMAN, 2008), as is verified in Tucanuçu [22, 23]. Tucanuçu *sciatic a.*, after crossing sciatic foramen, emits a *obturator a.*, whose distribution occurs in obturator structures and circumferences, in accordance with Baumel in Sisson; Grossman (2008) [23].

Nickel; Schummer; Seiferle (1977) and Baumel in Sisson; Grossman (2008) are unanimous in citing that *ischiatic a.* leaves pelvic cavity through homonymous foramen, as seen in Tucanuçu. Through sciatic foramen, *ischiaticus a.* emits *gluteal a.*, intended for muscles of gluteal region, in agreement with Nickel's citation; Schummer; Seiferle (1977). Baumel in Sisson; Grossman (2008) do not refer *gluteal a.* in birds [22, 23].

In Tucanuçu, after crossing sciatic foramen *sciatic a.* follows its course deeply into lateral thigh muscles, without emitting collateral branches, up popliteal fossa, always in close relationship of caudal proximity with sciatic n. and cranial with homonymous v., in disagreement with Nickel's citation; Schummer; Seiferle (1977) when state that *ischiatic a.*, after leaving ischial foramen, emits muscle branches and *trochanteric a.* as well, with Baumel in Sisson; Grossman (2008) who cites *trochanteric a.* and one *caudal femoral a.*, like branches of *ischiatic* [22, 23].

When entering popliteal fossa, *ischiatic a.* from Tucanuçu is called *popliteal a.*, according to Nickel's citations; Schummer; Seiferle (1977) and Baumel in Sisson; Grossman (2008) [22, 23].

Observations in Tucanuçu show that *popliteal a.* emits, *sural caudal a.* (caudally) and *cranial sural a.* (cranially), in agreement with Baumel in Sisson; Grossman (2008). However, this same author citate *sural a.* before popliteal fossa. Nickel; Schummer; Seiferle (1977) in turn, cites *deep femoral a.*, one *caudal femoral* and one *tibial a.* with branches of *popliteal a.* [23, 22].

According to Baumel in Sisson; Grossman (2008), *popliteal a.* emits *proximal genicular a.* and *distal nutritia of femur* and distal part gives rise to *medial tibial a.*, which emits *genicular medial a.* and follows inside gastrocnemius m. as *medial crural a.*. When leaving distally to popliteal fossa is divided into *tibial caudal* and *cranial tibial a.* [23].

Literary citation on branches of *popliteal a.* are confused, using different terminologies, apparently, to name same structures. Nickel; Schummer; Seiferle (1977) cites *deep femoral a.* and *tibial medial a.* as branches of *poplitea a.*, then *caudal femoral a.*, one *medial tibial a.* and one *cranial tibial a.* [22].

In Tucanuçu there is a relatively simpler disposition when *popliteal a.* issues two *surais*, *cranial* and *caudal Aa*, responsible for almost entire blood supply of leg, continuing close to caudal face from tibiotarsus bone proximal part, emitting *caudal genicular a.*

For Nickel; Schummer; Seiferle (1977), *cranial tibial a.* follows a distal course within gastrocnemius m. to form a tarsometatarsal network. *Caudal tibial a.* follows between caudal muscles of leg to tarsometatarsian network articulation [22].

Baumel in Sisson; Grossman (2008) states that *cranial tibial a.* is a continuation of *popliteal a.*, emitting *fibular a.* which crosses tibio-fibular interosseous foramen and enters extensor compartment of leg, without reaching tibiotarsometatarsal articulation [23].

In turn, Nickel; Schummer; Seiferle (1977) cites that *fibular a.* arises from *popliteal a.* and enters dorsal compartment of leg. After releasing all these branches, *popliteal a.* divides into middle third of leg in *Cranial Tibial* and *Lateral Tibial a.*, smaller, both forming *Tarsometatarsian* network [22].

In Tucanuçu, *popliteal a.* continues on caudal face of tibiotarsal bone, after issuing *surais Aa.*, emits *caudal genicular a.* following as *unique tibial a.* to tibiotarsometatarsal articulation, since *caudal tibial* branches into caudal structures of leg. After Tibiotarsometatarsiana articulation, the *cranial tibial a.* passes under retinaculum of cranial tibial m.. Medially to tendon of cranial tibial m., gaining cranial face of metatarsal bone, going to foot like *metatarsal a.*. Baumel in Sisson; Grossman (2008) states that opposite to proximal end of Tarsometatarsus, *cranial tibial a.* becomes *common metatarsodorsal a.*, responsible for foot vascularizing. Citations agree with observations in Tucanuçu, but in disagreement with Nickel; Schummer; Seiferle (1977) when affirming that the referred artery branches in the middle part of tarsometatarsus in dorsal and lateral metatarsals [22, 23].

Baumel in Sisson; Grossman (2008) states that at level of metatarsophalangeal articulation, borns *pulvinar Aa.* to metatarsal pads which form a plantar arterial arch. The digital arteries can come from *plantar arterial arch* or from *metatarsian a.* [23].

According to Nickel; Schummer; Seiferle (1977), *cranial tibial a.* follows its distal course to tibiotarsometatarsal articulation when crosses under tendon of cranial tibial m., becoming *dorsal metatarsal a.*, which forks into third distal of metatarsus to form *dorsal* and *lateral metatarsals Aa.*, which reach interdigital spaces. In Tucanuçu *metatarsal a.* is unique and goes from cranial face of metatarsus to metatarsophalangeal articulation, when emits medially, an *plantar a.* and *digital a.* laterally, for two medial fingers and then emits a *digital a.* to the side finger, following like *digital a.* for middle finger [22].

## V. CONCLUSION

The present study shows unprecedentedly relates about arteries of pelvic member in Tucanuçu (*Ramphastos toco albogularis*), showing that with regard to referred vessels, the findings are in agreement with the referred authors. The observations in Tucanuçu shows particular findings, since *femoral a.* is the middle branch of *external iliac a.*, the course of which runs sideways along edge of sinsacral bone to posterior thigh muscles, already lateral face, ventrally crosses *sciatic a.* from cranial to caudal, ending in caudolateral muscles of thigh and gluteal region. Thus, this work shows great similarity with domestic birds and particularities about this specie, contributing to anatomical description and understanding of an important blood vessel in Tucanuçu.

## REFERENCES

- [1] Pfrimer, G. A. Origem e distribuição das artérias da coxa e da perna de javali (*Sus scrofa* LINNAEUS, 1758) - Uberlândia. 2018. 70f. Tese - Universidade Federal de Uberlândia, Uberlândia, 2018.
- [2] Ragusa-Netto, J. Abundance and frugivory of the Toco toucan (*Ramphastos toco*) in a gallery Forest in Brazil's Pantanal. Brazilian Journal Biology. 2006; 66 (1):133-142.
- [3] Ragusa-Netto, J. Toco Toucan feeding ecology and local abundance in a habitat mosaic in the Brazilian cerrado. Ornitologia Neotropical. 2008. 19 (3). p. 345-359.
- [4] Sick, H. 1997. Ornitologia Brasileira. Nova Fronteira, Rio de Janeiro
- [5] Piacentini, V.Q., A. Aleixo, C.E. Agne, G.N. Maurício, J.F. Pacheco, G.A. Bravo, G.R.R. Brito, L.N. Naka, F. Olmos, S. Posso, L.F. Silveira, G.S. Betini, E. Carrano, I. Franz, A.C. Lees, L.M. Lima, D. Pioli, F. Schunck, F.R. Amaral, G.A. Bencke, M. Cohn-Haft, L.F.A. Figueiredo, F.C. Straube and E. Cesari. 2015. Annotated checklist of the birds of Brazil by the Brazilian Ornithological Records Committee / Lista comentada das aves do Brasil pelo Comitê Brasileiro de Registros Ornitológicos. Revista Brasileira de Ornitologia 23(2): 91–298. [http://www4.museu-goeldi.br/revistabromito/revista/index.php/BJO/article/view/1263/pdf\\_905](http://www4.museu-goeldi.br/revistabromito/revista/index.php/BJO/article/view/1263/pdf_905)
- [6] Pallinger, F. J.; Aprille, M. Tucanos e Araçaris Neotropicais. Editora Edelbra. 1ª ed. São Paulo, SP, 2015.
- [7] Antas, P. T. Z. Pantanal: guia de aves. Rio de Janeiro: Sesc, Departamento Nacional, 2004. disponível em <http://www.avespantanal.com.br/paginas/160.htm> Acesso em 22 de novembro de 2019.
- [8] Pizo, M. A.; Galetti, M. Métodos e perspectivas do estudo da frugivoria e dispersão de sementes por aves. In: TRAUBE, J.F.C.S; VON MATTER, S. (Org.). Ornitologia e conservação: ciência aplicada, técnicas de pesquisa e levantamento. Rio de Janeiro: Technical Books. 2010. p.492–504.
- [9] Fecchio, R. S. Análise biomecânica da aderência de diferentes sistemas adesivos ao estrato córneo queratinizado do bico de tucanos-toco (*Ramphastos toco*). 2011. 95f. Dissertação (Mestrado) - Faculdade de Medicina Veterinária e Zootecnia. Universidade de São Paulo (USP). São Paulo. 2010.
- [10] Castro, M. S.; Recco-Pimentel, S. M.; Rocha, G. T. Karyotypic characterization of Ramphastidae (Piciformes, Aves). Genetics and molecular biology. 25: 139–145. 2002.
- [11] Remsen Jr, J. V., Hyde, M. A.; Chapman, A. The diets of neotropical trogons, motmots, barbets and toucans. The Condor 95: 178-192. 1993.
- [12] Short, L. L.; Horne, J. F. M. Family Ramphastidae (Toucans). In: Del HOYO, J.; ELLIOT, A.; SARGATAL, J. (eds.). Handbook of the Birds of the World. Vol 7. Jacamars to Woodpeckers. Lynx Edicions: Barcelona, Spain. 2002. p.220-272.
- [13] Silva, J. N.; Azevedo, C. S. *Rattus rattus* (Mammalia: Rodentia) predation by *Ramphastos vitellinus* (Aves: Ramphastidae) in Santa Teresa Municipality, Espírito Santo, Brazil. Revista Brasileira de Ornitologia, v. 20, p. 156-157, 2012. Disponível em: <[http://revbrasilornitol.com.br/BJO/article/view/4708/pdf\\_627](http://revbrasilornitol.com.br/BJO/article/view/4708/pdf_627)> Acesso em: 22/ nov. 2019.
- [14] Howe, H.F.; Smallwood, J. Ecology of seed dispersal. Annual review of ecology and systematics. 13: 201-228. 1982.
- [15] Jordano, P., Galetti, M., Pizo, M. A.; Silva, W. R. Ligando frugivoria e dispersão de sementes à biologia da conservação. In: DUARTE, C.F., BERGALLO, H.G., DOS SANTOS, M.A. (eds.). Biologia da conservação: essências. São Paulo: Editorial RimA. 2006. p. 411-436.
- [16] Padula, C.R. Comportamento e preferência alimentar de tucanuços (*Ramphastos toco*) criados em cativeiro visando subsidiar programas de soltura. Botucatu, 2017. 50p. Dissertação (Mestrado em Animais Selvagens - Cirurgia) – Faculdade de Medicina Veterinária e Zootecnia, Campus de Botucatu, Universidade Estadual Paulista. 2017.



- [17] Redford, K.H. The empty forest. Bioscience. University of California Press. 42(6): 412-422. 1992
- [18] Marini, M. A.; Garcia, F. I. Conservação de aves no Brasil. Megadiversidade. Belo Horizonte, 1(1). 95-102, jul. 2005.
- [19] BirdLife International 2004. *Ramphastos toco*. The IUCN Red List of Threatened Species 2004: e.T22682164A34632293. Downloaded on 14 April 2020.
- [20] [https://www.icmbio.gov.br/portal/images/stories/comunicacao/publicacoes/publicacoes-diversas/livro\\_vermelho\\_2018\\_vol1.pdf](https://www.icmbio.gov.br/portal/images/stories/comunicacao/publicacoes/publicacoes-diversas/livro_vermelho_2018_vol1.pdf)
- [21] Baumel, J. J. Handbook of avian anatomy: Nomina Anatomica Avium. 2.ed. Cambridge, MA, USA: Nuttall Ornithological Club, 1993. 779p.
- [22] Nickel, R. Schummer, A.; Seiferle, E. Anatomy of the domestic birds. Berlin: Verlag Paul Parey, 1977. 202p.
- [23] Baumel J. J. Coração e vasos sanguíneos das aves. In: GETTY, R. (Ed.), Sisson/Grossman: anatomia dos animais domésticos (reimp.) 5. ed. Rio de Janeiro. Guanabara Koogan, 2008. v. 2, p.1842-1880.